

DETERMİNİNG THE RELATIONSHIP BETWEEN ANGLE OF ROOTS, CROWN FURCATION ROOF ANGLE, AND FURCATION DEFECTS USING CONE BEAM COMPUTERIZED TOMOGRAPHY

KÖKLER ARASI AÇI, KRON-FURKASYON ÇATISI ARASI AÇI VE FURKASYON DEFEKTLERİNİN BİRBİRLERİ İLE OLAN İLİŞKİLERİNİN KONİK İŞİNLİ BİLGİSAYARLI TOMOGRAFİ İLE BELİRLENMESİ

Yrd. Doç. Dr. Abdullah Seçkin ERTUĞRUL*
Dt. Yasin TEKİN*
Dt. Ahu DİKİLİTAŞ*

Dt Alihan BOZOĞLAN*
Dt. Hacer ŞAHİN*
Dt. Nazlı Zeynep ALPASLAN*

Yrd. Doç. Dr. Sami KARA**

Makale Kodu/Article code: 917
Makale Gönderilme tarihi: 05.10.2012
Kabul Tarihi: 11.01.2013

ABSTRACT

Objective: Furcation defects are complex and difficult periodontal problems to treat. This study analyzes the relationship between the angle of roots and crown furcation roof angle with different furcation defects at mandibular first molars using cone beam computerized tomography.

Material and Methods: Cone beam computerized tomography was taken from a total of 1042 patients. The measurements taken from all patients were divided into 3 groups according to their furcation defects. In the first group (G-1), horizontal defect depth was ≤ 3 mm; in the second group (G-2), horizontal defect depth was > 3 mm, and in the third group (G-3), horizontal defect depth was greater than the tooth's width.

Results: A total of 1042 patients (530 women and 512 men) were included in the study. The average patient age was 37.2. G-1 has 539 patients, G-2 has 301 patients, and G-3 has 202 patients. The angle of roots was measured for each of the three groups at 16.2° , 15.4° , and 12.9° , respectively. The crown furcation roof angle was measured for the three groups at 105.1° , 110.3° , and 121.9° , respectively.

Conclusion: Furcation defects can be more destructive as the angle of roots decreases and the crown furcation roof angle increases. Therefore, when the angle of root is less than 16.2° and crown furcation roof angle is higher than 105.1° , it is thought that mandibular molar teeth are susceptible to furcation defects, and that the furcation defects can be prevented by reducing the time between maintenance periods.

Keywords: Angle of roots, crown furcation roof angle, furcation defects, cone beam computerized tomography.

ÖZET

Amaç: Furkasyon defektleri anatomik ve morfolojik özellikleri nedeniyle kompleks periodontal sorunlardır ve periodontal tedavileri zordur. Bu çalışmanın amacı diş kökleri arası açısı, kron-furkasyon çatısı arası açısı ve furkasyon defektlerinin birbirleri ile olan ilişkilerinin mandibular birinci molar dişlerde konik ışınli bilgisayarli tomografi yöntemi kullanılarak belirlemektir.

Gereç ve Yöntemler: Konik ışınli bilgisayarli tomografi 652 bayan, 590 erkekten oluşan toplam 1042 bireyden alınmıştır. Alınan konik ışınli bilgisayarli tomografi'lerde her bireyin mandibular birinci molar dişlerde kökleri arası açısı, kron-furkasyon çatısı arası açısı ölçülmüş ve furkasyon bölgesi radyolojik olarak değerlendirilmiştir. Yapılan ölçümlerde bireyler furkasyon defektlerine göre 3 gruba ayrılmıştır. 1. grup: horizontal defekt derinliği ≤ 3 mm, 2. grup: horizontal defekt derinliği > 3 mm, 3. grup: horizontal defekt derinliği diş genişliğinden fazla olarak belirlenmiştir.

Bulgular: Çalışmaya yaş ortalaması 37.2 olan toplam 1042 birey dâhil edilmiştir. Grup 1'de 539 hasta, Grup 2'de 301 hasta ve Grup 3'de 202 hasta bulunmaktadır. Kökleri arası açısı 1., 2. ve 3. gruplarda sırasıyla 16.2° - 15.4° - 12.9° olarak kron-furkasyon çatısı arası açısı ise 1., 2. ve 3. gruplarda sırasıyla 105.1° - 110.3° - 121.9° olarak ölçülmüştür.

Sonuç: Konik ışınli bilgisayarli tomografi gün geçtikçe dental kliniklerde kullanımı artan radyoloji görüntüleme yöntemlerindedir. Birçok periodontal hastalığın teşhisinde ve furkasyon problemlerinin belirlenmesinde konik ışınli bilgisayarli tomografi kullanılabilir. Furkasyon problemleri, kökleri arası açısı azaldığı zaman ve kron-furkasyon çatısı arası açısı arttığı zaman daha yıkıcı hal alabilmektedir. Kökleri arası açısı 17.6° 'den küçük olduğu ve kron-furkasyon çatısı arası açısı 103.4° 'den büyük olduğu birinci mandibular molar dişlerin furkasyon problemleri oluşmasına yatkın oldukları, bu özellikteki dişlerin idame sürelerinin kısa tutulması ile furkasyon problemi oluşmadan önenebileceği düşünülmektedir.

Anahtar Kelimeler: Kökleri arası açısı, kron-furkasyon çatısı arası açısı, furkasyon defektleri, konik ışınli bilgisayarli tomografi.

* Yüzüncü Yıl Üniversitesi, Diş Hekimliği Fakültesi, Periodontoloji AD..

** Yüzüncü Yıl Üniversitesi, Diş Hekimliği Fakültesi, Oral Diagnoz ve Radyoloji AD



INTRODUCTION

Bone defects formed as a result of the pathological resorption of the bone between the roots of multi-rooted teeth are defined as furcation defects (FD).¹ Dentine extensions, dentine enamels, and structural abnormalities such as cementum, pulpal reasons, occlusal trauma, teeth and furcation morphology (entrance of furcation, root concavities, furcation roof, furcation depth, and root body), alveolar bone structure, developmental collapsed areas on teeth, the relationship of the roots, and the distance of the roots play a role in the etiology of FD.^{2,3} The narrowness of the distance between the roots, the depth of the furcation entry, and the inner surface of the root make it significantly more difficult for mechanical cleaning to be carried out during periodontal treatment.⁴ FDs significantly increase the risk of losing teeth.⁵⁻⁷ Traditional periodontal treatment methods are not sufficient alone in treating teeth with FD. Studies have shown that the loss of multi-rooted teeth because of FDs are more frequently seen when compared with teeth with only one root.^{8,9}

Based on the size of the FD lesion and its severity, treatment is carried out using conservative, resective or regenerative approaches. In Goldman's classification system, Class I or early Class II FDs require applications such as initial periodontal treatment, which comprise tooth and root surface cleaning and regenerative treatment processes. In Class III or advanced Class II FDs, the initial periodontal treatment is followed by resective or regenerative treatment approaches such as tunnel preparation, root resection, and hemisection/bisection.¹⁰⁻¹⁵

In the diagnosis of FD, aside from clinical evaluation, radiological evaluation is very important. The radiological examinations used in the diagnosis of FD include periapical films, panoramic films, and cone beam computerized tomography (CB-CT).^{16,17} Computerized tomography is defined as cross-section radiography via computer. This is a special technique used to provide radiographs that show only one section or area of a body. Each cross-section focuses on the tissue and the structures are shown clearly.¹⁸ Just like in conventional radiology, X-rays are used in CB-CT. However, in contrast to conventional radiology, the X-rays are properly limited so that their distribution is minimal, which ensures that the

difference in tissue density can be seen more clearly in a CB-CT. For this reason, structures that show different densities such as edema, hematoma, and hemorrhage can be viewed precisely with a CB-CT and their densities can be measured.¹⁹

Another aspect of the system that is superior to conventional imaging is that by eliminating superposition with the sectional examination method, a better view of the area of interest can be obtained.^{20,21} In recent years, CB-CT has been used in determining periodontal prognosis and in the diagnosis of FD.^{22,23} In FDs, the position of the roots and the relationship between the furcation roof and teeth crowns are very important. By determining this relationship, it is believed that the periodontal treatment of FD can be improved. Our study contends that CB-CT can aid in determining the relationship between angle of roots (RA) and crown furcation roof angle (CFA) at mandibular first molar teeth with different diagnosed FDs.

MATERIAL AND METHODS

Subject Selection

In total, 1042 patients who have had CB-CT taken between the years 2010-2012 for reasons such as dental implant planning, determining impacted tooth position, and evaluating pathological structures, and who have applied for examination in the Yüzüncü Yıl University Faculty of Dentistry, have been included in this study. Patients with evidence of nasopalatine pathology (e.g., nasopalatine duct cyst) and low quality imaging, such as scattering of the bony borders, were excluded. The evaluation of the data used in the study has been carried out by an investigator in order to provide calibration on CB-CT (ASE).

Measurements were taken from only one tooth per patient. Patients with first molar teeth that did not have a mesial and distal contact, that had lost their antagonists, that had dental cavities or restorations in the contact teeth and the teeth themselves, patients with bruxism, patients who smoked, patients who have been diagnosed with aggressive periodontitis, and those with teeth that had a pathological state close to the first molar were excluded. For this study, approval from the Human Ethics Research Committee of Yüzüncü Yıl University (YYU-200912) was sought and issued.



Measurements of CB-CT

Measurements were made with computer software on CB-CT (3D eXam Gendex Imaging Sciences-Chicago, IL, USA) cross-sectional images of the mandible. Magnification loops (2.5) were used to make each measurement. Subsequently, they were exposed to radiations with 120 KV (peak) and 5 mA for 4.8 seconds. The resolution was set at 0.4 mm. The data images were reconstructed using the built-in software package on a desktop computer.

RA was measured sagittal CB-CT images at selected mandibular first molars. RA is the angle between the line drawn from the highest crown point of the furcation entrance to the furthest mesial curvature point of the mesial root, and the line drawn at the highest crown point of the furcation entrance to the furthest mesial curvature point of the mesial root at a sagittal CB-CT images where the RA mesial and the distal root is the widest (Figure 1).

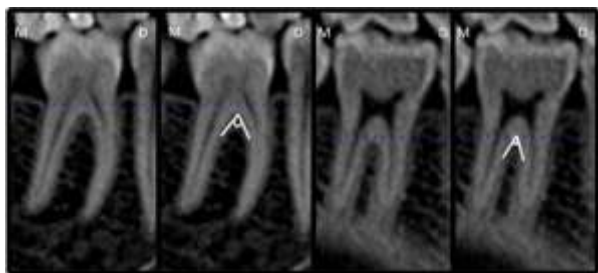

Figure 1. Angle of roots was measured sagittal CB-CT images at selected mandibular first molar teeth. Angle of roots is the angle between the line drawn from the highest crown point of the furcation entrance to the furthest mesial curvature point of the mesial root and the line drawn at the highest crown point of the furcation entrance to the furthest mesial curvature point of the mesial root at a sagittal CB-CT images view where the angle of roots mesial and the distal root is the widest. M, Mesial; D, Distal.

CFA was also measured transverse cross-sectional CB-CT images at selected mandibular first molars. CFA is the angle of the line drawn between the furcation entry point and the highest buccal protrusion point on the buccal face of the crown on the image where the furcation roof is the shortest, and the line drawn from the most apical points and the buccal furcation entry points with the tooth occlusal table in the transverse cross-sectional CB-CT image on CB-CT of the selected first molars (Figure 2).

Participants in the study were divided into three groups according to their FDs: Group 1 (G-1) (horizontal defect depth is lower than 3 mm.), Group 2 (G-2) (horizontal defect depth is higher than 3 mm), and Group 3 (G-3) (horizontal defect depth surpasses the whole of the tooth width).¹⁰

Statistical Analysis

The data were analyzed using a statistical package computer program (SPSS 16.0). First, a Kolmogorov-Smirnov normality test was used. A non-parametrical test (Mann-Whitney U test with Bonferroni correction) was used to compare ages, RA, and CFA between groups. The correlations between parameters were analyzed with Pearson correlation coefficient ($p < 0.05$ was considered statistically significant).

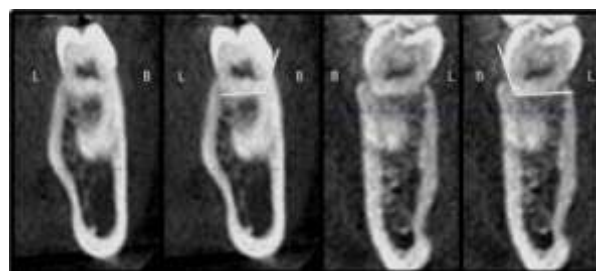


Figure 2. Crown furcation roof angle was measured cross-sectional CB-CT images at selected mandibular first molar teeth. Crown furcation roof angle, is the angle of the line drawn between the furcation entry point and the highest buccal protrusion point on the buccal face of the crown on the image where the furcation roof is the shortest, and the line drawn from the most apical points and the buccal and lingual furcation entry points with the tooth occlusal table in the cross-sectional CB-CT images on cone beam computerized tomography of the chosen first molar teeth. B, Bukkal; L, Lingual.




Figure 3. A) The comparison of the Crown furcation roof angle (CFA) at first molar teeth in groups by cone beam computerized tomography. B) The comparison of the Angle of roots (RA) at first molar teeth in groups by cone beam computerized tomography.

* The groups are statistically different from each other, $p < 0.05$



RESULTS

Images from a total of 1042 patients (552 women and 490 men, with a mean age of 37.2 years, ranging between 19 and 55 years) were included in the study. Patients were distributed across the major groups, as follows: G-1 had 539 patients (260 men and 279 women), G-2 had 301 patients (140 men and 161 women), and G-3 had 202 patients (112 men and 90 women). Demographic data for all patients is presented in Table 1. When the age data of patients who participated in the study were evaluated, it was determined that the groups were statistically different from each other according to ages ($p < 0.05$). Results show that the mean ages were statistically higher in the G-3 group, and statistically lower in the G-1 group, when compared with other groups.

Table 1.: Demographic Characteristics of Study Groups.

	Group 1 (G-1)	Group 2 (G-2)	Group 3 (G-3)	<i>p</i> value
Number of patients (n)	539	301	202	-
Age (years) (Mean±SD)	31.4±3.2	35.2±5.1	41.4±4.4	<0.05
Gender Female/Male	279/260	161/140	90/112	-

Group 1 (G-1) (horizontal defect depth is lower than 3 mm.);
Group 2 (G-2) (horizontal defect depth is higher than 3 mm);
Group 3 (G-3) (horizontal defect depth surpasses the whole
of the tooth width

The RA and CFA data of the study groups are presented in Figure 3. When RA is evaluated in all patients, it averages 16.2° in the G-1 group, 15.4° in the G-2 group, and 12.9° in the G-3 group. CFA was measured at 105.1° in the G-1 group, 110.3° in the G-2 group, and 121.9° in the G-3 group. When the RA and CFA values between groups were evaluated, results show that the groups were significantly different from each other ($p < 0.05$). RA was significantly lower in the G-3 group when compared with other groups, and significantly higher in the G-1 group when compared with other groups ($p < 0.05$). CFA was significantly lower in the G-1 group when compared with other

groups, and significantly higher in the G-3 group when compared with other groups ($p < 0.05$).

When the correlation between age and FD was evaluated, results showed that when patient age increased, FDs also increased. When the relationship between RA and CFA is examined, we found that when RA increased, FDs decreased, and when CFA increased, FDs increased. A strong negative correlation existed between RA and FD ($r = -0.714$), and strong positive correlation between CFA and FD ($r = 0.704$).

DISCUSSION

There are many studies in the literature that compare CB-CT with conventional radiological methods in diagnosing FDs.²⁴⁻²⁶ However, this study is the first to classify FDs with the help of CB-CT radiological imaging and which compares RA and CFA in the groups obtained, following classification.

An FD is an important pathological state which prevents the successful treatment of periodontal disease.^{27,28} Intraoral radiographs have been used in determining FDs in general. Due to the fact that intraoral radiographs present two-dimensional images, such methods have started to give way to CB-CT radiological methods which produce three dimensional images.^{26,29,30} CB-CT images are preferred in dental clinics because they require less radiation exposure and produce better images.^{31,32} In most cases, determining and classifying FDs by CB-CT is fully successful.^{24,29} In addition to FDs, in many periodontal pathologies (dehiscences and fenestrations), diagnosis is carried out by CB-CT. Early diagnosis of FDs is very important in the success rate of periodontal treatment.^{33,34}

Enamel abnormalities, furcation morphology, the relationship of the roots with each other, and the distance of the roots to each other, are some of the factors that play a role in FD etiology.^{2,3,35} These factors make FDs significantly more difficult for mechanical cleaning and leads to more dental plaque accumulation in the furcation area.^{36,37} This information makes us think that the morphology of the furcation area carries a very important role in relation to periodontal diseases and FDs.

Our results showed that when RA increased, the angle between the concave points of the roots



also increased. When RA values increased, the amount of periodontal tissues destruction decreased. This relationship can be defined with more than one hypothesis. Our first hypothesis is that when RA decreases, the distance between the roots also decreases, which makes it more difficult to reach furcation areas. Periodontal treatment tools are being produced in certain dimensions. In furcation areas where periodontal treatment tools cannot reach, dental plaque cannot be eliminated and destruction in periodontal tissue increases. In our study, the RA value was determined to be the highest in the G-1 group and lowest in the G-3 group. We believe that the RA angle is important in both the increase of defects and the beginning of FDs. This hypothesis is supported by the studies carried out by Hou et al.³⁹, many teeth in their study produced a furcation entry in mandibular molars width less than 0.82 mm. Furcation entry points were very important in periodontal treatment when considering that the smallest periodontal curette was 0.75-1.1 mm. Our second hypothesis is that when RA decreased, bone mass in this area also decreased. The decreased bone mass may also lead to the decrease in the resistance of the bone against occlusal forces. Due to the fact that the bone cannot compensate for such forces, it is thought that in teeth with low RA, there will be severe resorption in the furcation area. Our third hypothesis is that when RA decreases, periodontal tissue that prevents bone destruction in the furcation area also decreases, which causes more destruction.

When the relationship between the ages and FDs of the subjects participating in our study was examined, it has been found out that when the age data of the subjects participating in the study increased the FDs is more destructive. The average age of the G-3 group is higher than the groups G-1 and G-2. Similarly, the average ages of the G-2 group is higher than the average ages of the subjects within the G-1 group. In this case, it is determined that age plays a role in the ethiology of FDs and in subjects who are older a more frequent FDs formation can be observed. CFA and RA which are evaluated in this are study, are not factors that can change due to age. However if we think that FDs changes due to age, it can be assumed that it would be more correct to form a study in groups whose age data are similar. As the studies are carried out over the CB-CT's taken due to

different reasons between the dates mentioned in the material and methods section of our study, and as we believe that the number of patients were sufficient, groups with similar age data groups but whose numbers are close to each other were not formed. As a result the CFA and RA angles determined in our study and their relationship with FDs could have been affected by the age data.

Our study also used CFA in determining the concavity level that might increase plaque accumulation on the buccal surface of the tooth. We expect to examine whether such an anatomical condition is important for FDs or not. CFA was lowest in the G-1 group highest in the G-3 group. This situation can also be explained by a few hypotheses. Our first hypothesis pertaining to CFA is that when CFA increases, an area which is very difficult to be cleaned is created between the most buccal point of the crown and the furcation entry; in this area, even more dental plaque accumulates. If the dental plaque that accumulates cannot be eliminated, periodontal problems can develop in furcation regions. As this situation advances, resorption in bone occurs and FDs can develop. Our second hypothesis states that teeth that have more concave shapes cannot, physiologically, be cleaned. As CFA increases, concavity increases, and the area between the most buccal point and the furcation entry cannot be cleaned through physical cleaning of oral tissues.

CONCLUSION

In routine radiological evaluations, CFA was higher than 105.1° and RA was lower than 16.2°. It is believed that such a situation led to the development of FD in teeth, and it can be thought that maintenance intervals might need to be kept shorter. With the aid of CB-CT, and by precisely determining the furcation-root morphologies, we believe that periodontal diagnoses, treatment choices, prognoses, and maintenance protocols can be readily determined.

ACKNOWLEDGMENTS AND SOURCE OF FUNDING

This study was self-funded by the authors. The authors thank the School of Dentistry at Yuzuncu Yil University for its support. The authors declare that they have no conflicts of interest.



REFERENCES

- 1) Cattabriga M, Pedrazzoli V, Wilson TG Jr. The conservative approach in the treatment of furcation lesions. *Periodontol 2000* 2000;22:133-53.
- 2) Müller HP, Eger T, Lange DE. Management of furcation-involved teeth. A retrospective analysis. *J Clin Periodontol* 1995;22:911-7.
- 3) Abitbol T, LoPresti J, Santi E. Influence of root anatomy on periodontal disease. *Gen Dent* 1997;45:186-9.
- 4) Wang HL, Burgett FG, Shyr Y, Ramfjord S. The influence of molar furcation involvement and mobility on future clinical periodontal attachment loss. *J Periodontol* 1994;65:25-9.
- 5) Wang HL, O'Neal RB, Thomas CL, Shyr Y, MacNeil RL. Evaluation of an absorbable collagen membrane in treating Class II furcation defects. *J Periodontol* 1994;65:1029-36.
- 6) McGuire MK, Nunn ME. Prognosis versus actual outcome. III. The effectiveness of clinical parameters in accurately predicting tooth survival. *J Periodontol* 1996;67:666-74.
- 7) McGuire MK, Nunn ME. Prognosis versus actual outcome. II. The effectiveness of clinical parameters in developing an accurate prognosis. *J Periodontol* 1996;67:658-65.
- 8) Papapanou PN, Tonetti MS. Diagnosis and epidemiology of periodontal osseous lesions. *Periodontol 2000* 2000;22:8-21.
- 9) DeSanctis M, Murphy KG. The role of resective periodontal surgery in the treatment of furcation defects. *Periodontol 2000* 2000;22:154-68.
- 10) Ammons WF Jr, Harrington GW. Furcation: The problem and it's management. In: *Clinical periodontology*, Ninth ed, Eds Newman MG, Takei HH, Carranza FA: WB Saunders Company, Philadelphia 2002. p. 825-39.
- 11) Vandersall DC, Detamore RJ. The mandibular molar class III furcation invasion: a review of treatment options and a case report of tunneling. *J Am Dent Assoc* 2002;133:55-60.
- 12) Patel S, Kubavat A, Ruparelia B, Agarwal A, Panda A. Comparative evaluation of guided tissue regeneration with use of collagen-based barrier freeze-dried dura mater allograft for mandibular class 2 furcation defects (a comparative controlled clinical study). *J Contemp Dent Pract* 2012;13:11-5.
- 13) Rüdiger SG. Mandibular and maxillary furcation tunnel preparations--literature review and a case report. *J Clin Periodontol* 2001;28:1-8.
- 14) Anderegg CR, Metzler DG. Retention of multi-rooted teeth with class III furcation lesions utilizing resins. Report of 17 cases. *J Periodontol* 2000;71:1043-7.
- 15) Park JB. Hemisection of teeth with questionable prognosis. Report of a case with seven-year results. *J Int Acad Periodontol* 2009;11:214-9.
- 16) Tammsalo T, Luostarinen T, Vähätalo K, Neva M. Detailed tomography of periapical and periodontal lesions. Diagnostic accuracy compared with periapical radiography. *Dentomaxillofac Radiol* 1996;25:89-96.
- 17) Vandenberghe B, Jacobs R, Yang J. Detection of periodontal bone loss using digital intraoral and cone beam computed tomography images: an in vitro assessment of bony and/or infrabony defects. *Dentomaxillofac Radiol* 2008;37:252-60.
- 18) Whaites E, *Essentials of Dental Radiography and Radiology*, London, 2nd Edition. Churchill Livingstone, 1996. p. 143-51.
- 19) White SC, Pharoah MJ, *Oral Radiology: Principles and Interpretation*, St. Louis, Missouri, 5th Edition. Mosby, 2004. p. 191-255.
- 20) Ohman A, Kivijärvi K, Blombäck U, Flygare L. Pre-operative radiographic evaluation of lower third molars with computed tomography. *Dentomaxillofac Radiol* 2006;35:30-5.
- 21) Pawelzik J, Cohnen M, Willers R, Becker J. A comparison of conventional panoramic radiographs with volumetric computed tomography images in the preoperative assessment of impacted mandibular third molars. *J Oral Maxillofac Surg* 2002;60:979-84.
- 22) Walter C, Kaner D, Berndt DC, Weiger R, Zitzmann NU. Three-dimensional imaging as a pre-operative tool in decision making for furcation surgery. *J Clin Periodontol* 2009;36:250-7.
- 23) Walter C, Weiger R, Zitzmann NU. Accuracy of three-dimensional imaging in assessing maxillary molar furcation involvement. *J Clin Periodontol* 2010;37:436-41.
- 24) Vandenberghe B, Jacobs R, Yang J. Detection of periodontal bone loss using digital intraoral and



- cone beam computed tomography images: an in vitro assessment of bony and/or infrabony defects. *Dentomaxillofac Radiol* 2008;37:252-60.
- 25) Hu KS, Choi DY, Lee WJ, Kim HJ, Jung UW, Kim S. Reliability of two different presurgical preparation methods for implant dentistry based on panoramic radiography and cone-beam computed tomography in cadavers. *J Periodontal Implant Sci* 2012;42:39-44
- 26) de Faria Vasconcelos K, Evangelista KM, Rodrigues CD, Estrela C, de Sousa TO, Silva MA. Detection of periodontal bone loss using cone beam CT and intraoral radiography. *Dentomaxillofac Radiol* 2012;41:64-9.
- 27) Hishikawa T, Izumi M, Naitoh M, *et al.* The effect of horizontal X-ray beam angulation on the detection of furcation defects of mandibular first molars in intraoral radiography. *Dentomaxillofac Radiol* 2010;39:85-90.
- 28) Walter C, Weiger R, Zitzmann NU. Periodontal surgery in furcation-involved maxillary molars revisited--an introduction of guidelines for comprehensive treatment. *Clin Oral Investig* 2011;15:9-20.
- 29) Misch KA, Yi ES, Sarment DP. Accuracy of cone beam computed tomography for periodontal defect measurements. *J Periodontol.* 2006;77:1261-6.
- 30) Çakur B, Sümbüllü MA. Konik işinli bilgisayarlı tomografi ile submandibular tükürük bezi taşı görüntülemesi. *Atatürk Üniv Dis Hek Fak Derg* 2010;203:194-7.
- 31) Mozzo P, Procacci C, Tacconi A, Martini PT, Andreis IA. A new volumetric CT machine for dental imaging based on the cone-beam technique: preliminary results. *Eur Radiol* 1998;8:1558-64.
- 32) Schulze D, Heiland M, Thurmann H, Adam G. Radiation exposure during midfacial imaging using 4- and 16-slice computed tomography, cone beam computed tomography systems and conventional radiography. *Dentomaxillofac Radiol* 2004;33:83-6.
- 33) Waerhaug J. The furcation problem. Etiology, pathogenesis, diagnosis, therapy and prognosis. *J Clin Periodontol* 1980;7:73-95.
- 34) Müller HP, Eger T. Furcation diagnosis. *J Clin Periodontol* 1999;26:485-98.
- 35) Santana RB, Uzel MI, Gusman H, Gunaydin Y, Jones JA, Leone CW. Morphometric analysis of the furcation anatomy of mandibular molars. *J Periodontol* 2004;75:824-9.
- 36) dos Santos KM, Pinto SC, Pochapski MT, Wambier DS, Pilatti GL, Santos FA. Molar furcation entrance and its relation to the width of curette blades used in periodontal mechanical therapy. *Int J Dent Hyg* 2009;7:263-9.
- 37) Otero-Cagide FJ, Long BA. Comparative in vitro effectiveness of closed root debridement with fine instruments on specific areas of mandibular first molar furcations. I. Root trunk and furcation entrance. *J Periodontol* 1997;68:1093-7.
- 38) Hou GL, Chen SF, Wu YM, Tsai CC. The topography of the furcation entrance in Chinese molars. Furcation entrance dimensions. *J Clin Periodontol* 1994;21:451-6.

Yazışma Adresi:

Abdullah Seçkin ERTUĞRUL
Yuzuncu Yil University Faculty of Dentistry
Department of Periodontology
Campus, 65080 Van, TURKEY
E-mail: ertugrulseckin@yahoo.com,
ertugrul@yyu.edu.tr

