



SURGICAL TREATMENT OF PEDIATRIC PERIPHERAL GIANT CELL GRANULOMA: A CASE REPORT

PEDİATRİK PERİFERAL DEV HÜCRELİ GRANÜLOMANIN CERRAHİ TEDAVİSİ: OLGU RAPORU

Yrd. Doç. Dr. Ömür DERECİ*

Prof. Dr. Özgül PAŞAOĞLU **

Prof. Dr. Sinan AY*

Makale Kodu/Article code: 1930
Makale Gönderilme tarihi: 21.10.2014
Kabul Tarihi: 2603.2015

ÖZET

Periferal dev hücreli granüloma diş etinde ortaya çıkan reaktif bir lezyondur. Dental plak, diş taşı, uygun olmayan restorasyonlar ve mikrotravma hikayesi gibi lokal faktörlerin periferal dev hücreli granüloma oluşumunda rol oynadıkları düşünülmektedir. Periferal dev hücreli granüloma her yaşta görülmesine rağmen çocukluk çağında göreceli olarak daha az görülmektedir. Bu olgu raporunda bir pediatrik periferal dev hücreli granülomanın cerrahi tedavisi sunulmuş ve histopatolojik özellikleri incelenmiştir.

Anahtar Kelimeler: Periferal dev hücreli granüloma, pediatrik, dev hücre, reaktif

ABSTRACT

Peripheral giant cell granuloma (PGCG) is a reactive lesion which occurs on gingiva. Local factors such as inappropriate dental restorations, dental plaque and microtraumas are considered to be responsible for the occurrence of the lesion. Although PGCG may be seen in all decades of life, pediatric form is relatively rare. In this case report, a pediatric PGCG is presented with histopathological features.

Key words: Peripheral giant cell granuloma, pediatric, giant cell, reactive lesion

INTRODUCTION

Peripheral giant cell granuloma (PGCG) is a benign enlargement, which is strictly located on gingiva. It is a relatively common reactive lesion with a sessile or pedunculated base and red-pink color.¹ PGCG is mostly located on premolar-molar region of the mandible.²⁻⁴ It has a predilection for female young adults.

PGCG is thought to arise from periodontal ligament with irritational effects of local factors such as dental plaque, calculus or inappropriate dental restorations.⁵ Microscopic and morphological features of PGCG is well-documented in adult population. However, the occurrence of PGCG in pediatric population is uncommon. In this case report, a PGCG lesion in a 9-year-old child is presented.

CASE REPORT

A 9-year-old female patient was referred to Eskişehir Osmangazi University, Faculty of Dentistry, Department of Oral and Maxillofacial Surgery with a chief complaint of pain on chewing on the left side of her lower jaw. Clinical intraoral examination revealed an exophytic, red-colored and lobulated mass protruding from gingival regions of 1st. and 2nd. left premolars (Figure 1). Lesion almost covered the occlusals of premolars and therefore, eruption of permanent premolars were compromised. Bone erosion or resorption was not observed on panoramic radiography (Figure 2). Medical anamnesis was non-contributory.

Lesion was excised under local anesthesia with a provisional diagnosis of peripheral giant cell granuloma. Post-surgical specimen was bluish-reddish

* Eskişehir Osmangazi University, Faculty of Dentistry, Department of Oral and Maxillofacial Surgery

** Eskişehir Osmangazi University, Faculty of Medicine, Department of Pathology



in color. Histopathologic examination revealed osteoclast-like multinuclear giant cells and numerous mononuclear cells with increased mitotic activity dispersed in a collagenous connective tissue stroma (Figure 3). There were also marked inflammatory reaction and reactive bone formation with osteoblastic rimming (Figure 4).

Healing was uneventful at postoperative 7th. day (Figure 5). Patient underwent a 6-month follow-up period. There was no sign of recurrence at postoperative 6. Month (Figure 6).

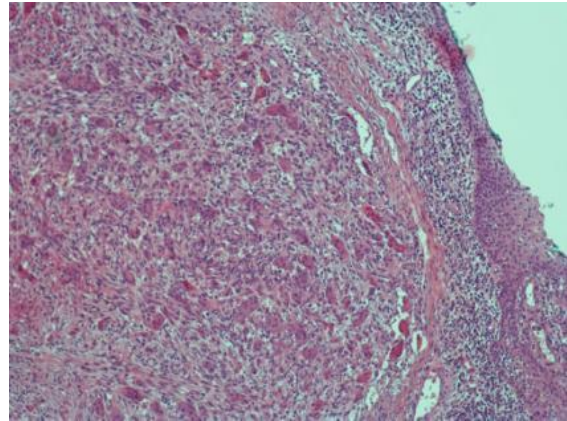


Figure 3. Multinucleate giant cells and mononuclear stromal cells were main components of the lesion. (HEX100)

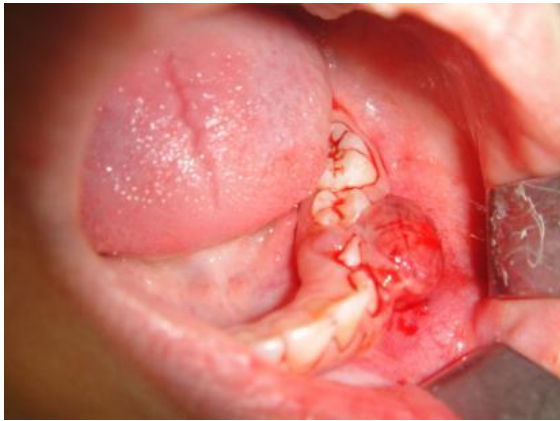


Figure 1. Intraoral examination revealed exophytic, red-colored lesion protruding from gingival region of 1th. and 2nd. left premolars. The lesion obstructed the eruption pathways of premolar teeth.

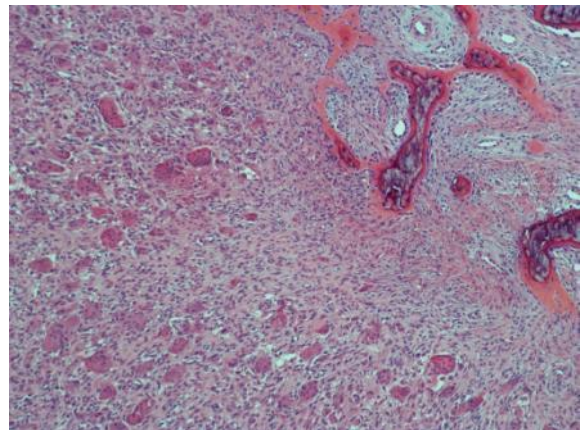


Figure 4. Inflammatory infiltration and reactive bone formation with evident osteoblastic rimming were present in pediatric peripheral giant cell granuloma. (HEX100)

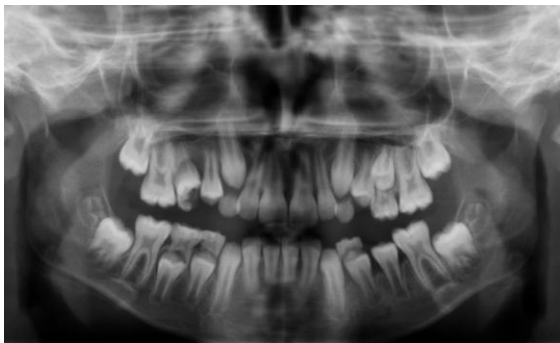


Figure 2. There were no distinctive radiologic manifestations of the lesion on left premolar region on panoramic radiography.

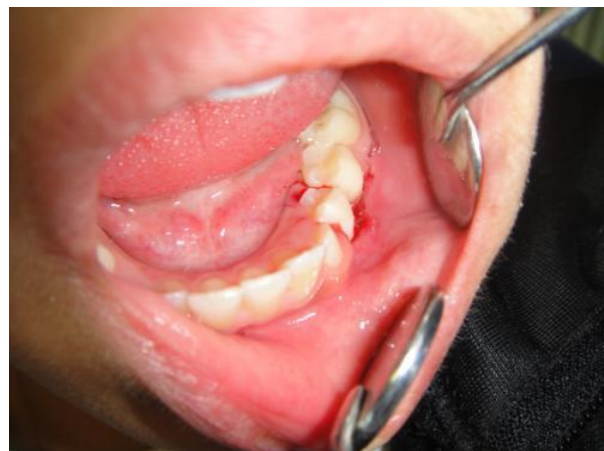

Figure 5. Healing was uneventful at postoperative 7th. day.

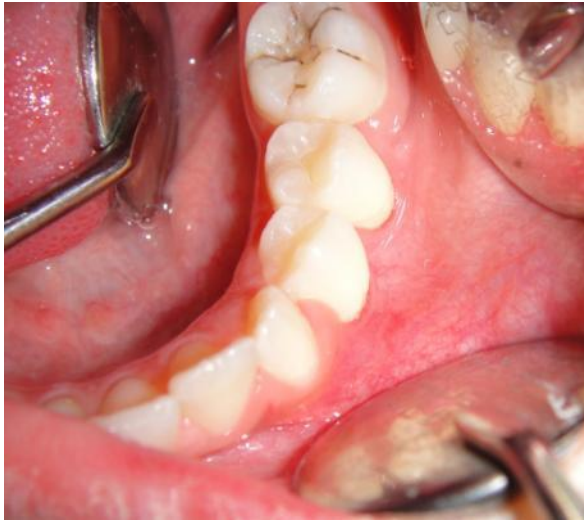

Figure 6. There was no sign of recurrence in intraoral examination after 6 months follow-up period.

DISCUSSION

PGCG is a tumor-like mucosal-gingival enlargement with soft or firm consistency and is only seen in oral region.⁶ Cervical bone resorption has also been reported in several cases.⁷ It is composed of ovoid-spindle mononuclear mesenchymal cell proliferation and multinuclear osteoclast-like giant cells in a collagenous stroma. Multinuclear cells may include many nuclei. Stromal mesenchymal cells have increased mitotic activity. There are multiple bleeding zones throughout the lesion. The covering mucosa may be ulcerated due to the masticatory forces. A thick connective tissue layer separates mucosa and giant cell proliferation. Acute or chronic inflammatory infiltration and reactive bone production can also be seen.⁸

Various theories have been postulated in order to explain giant cells in PGCG. Bhaskar et al.⁹ suggested that giant cells are formed by phagocytic reaction which occurs as a response to mucosal bleeding. It is also suggested that giant cells of PGCG may be recruited by foreign body reaction.¹⁰ Several authors suggested that giant cells of peripheral and central giant cell granuloma sustained osteoblastic properties.^{11,12} Giant cells in PGCG were classified in 2 types. Type 1 giant cells have a high quantity of eosinophilic cytoplasm and many active nuclei. In type 2 cells, nuclear boundaries are indefinite and there is distinct hyperchromatism in nucleus.¹³

Stromal cells of PGCG are diffusely dispersed in collagen bundles of connective tissue. Two types of stromal cells were described; Type 1 cells have distinct nucleolus and large ovoid vesicular nuclei.³ Type 2 stromal cells are spindle-formed cells similar to fibroblasts and show histologic characteristics of fibroblasts. Type 1 stromal cells were considered to be latent proliferative osteoblasts.¹⁴

Although local factors such as dental plaque calculus, microtraumas, ill-fitting dentures and restorations and food impaction were considered to be responsible for the induction and initiation of the lesion, etiopathogenesis have not been fully understood. There is no consensus regarding the origin of PGCG. It is generally considered as a reactive lesion.^{7,14}

PGCG can be almost seen in all decades of life. The occurrence in pediatric population is uncommon, however, it is well documented.^{3,5,15-17} Buchner et al.¹⁵ reported that PGCG comprised %20 of 223 biopsied pediatric gingival lesions in their study, indicating a relatively low incidence according to the rest of the biopsied gingival lesions. PGCG may exhibit aggressive behavior in pediatric population. Pandolfi et al.¹⁶ reported a case of aggressive pediatric -PGCG which displaced related teeth and had active bleeding with mastication. In the present case, patient and her family were unaware of the lesion and there were no definite data regarding the duration of the lesion. There was also bleeding with mastication and the lesion was covering the occlusal surfaces of erupting premolars, acting as an obstruction for fully eruption of permanent premolars. However, present case was not regarded as an aggressive lesion due to the incomplete data about duration.

In conclusion, pediatric PGCG is an uncommon benign reactive lesion of which etiopathogenesis is not fully understood. It is treated with surgical excision and curettage similar to the conventional PGCG. Recurrence is low similar to other gingival reactive overgrowths, however, follow-up is recommended.

REFERENCES

1. Shafer WG, Hine MK, Levy BM. Textbook of Oral Pathology. 4th. ed., Philadelphia; W.B. Saunders:1983

2. Motamedi MH, Eshghyar N, Jafari SM, Lassemi E, Navi F, Abbas FM, Khalifeh S, Eshkevari PS. Peripheral and Central Giant Cell Granulomas of the Jaws: A Demographic Study. *Oral Surg Oral Med Oral Pathol Oral Radiol Endod* 2007; 103: e39-43.
3. Katsikeris N, Kakarantza-Angelopoulou E, Angelopoulos AP. Peripheral Giant Cell Granuloma. Clinicopathologic Study of 224 New Cases and Review of 956 Reported Cases. *Int J Oral Maxillofac Surg* 1988; 17: 94-9.
4. Yalçın E, Ertaş Ü, Altaş S. Periferal Dev Hücreli Granüloma: Retrospektif Çalışma. *J Dent Fac Atatürk Uni* 2010; 20: 34-7
5. Giansanti JS, Waldron CA. Peripheral Giant Cell Granuloma: Review of 720 Cases. *J Oral Surg* 1969;27:787-91.
6. Cawson RA, Eveson JW. *Oral Pathology and Diagnosis*. 1st ed., London; William Heinemann Medical Books:1987
7. Nedir R, Lombardi T, Samson J. Recurrent Peripheral Giant Cell Granuloma Associated with Cervical Resorption. *J Periodontol* 1997;68:381-4.
8. Neville BW, Damm DD, Allen CM, Bouquot JE. *Oral and Maxillofacial Pathology*. 3rd ed., Philadelphia: W.B Saunders Company; 2002. p. 449-50
9. Bhaskar SN, Cutright DE, Beasley JD, Perez B. Giant Cell Reparative Granuloma (Peripheral): Report of 50 Cases. *J Oral Surg* 1971; 29: 110-5.
10. Thompson SH, Bischoff P, Bender S. Central Giant Cell Granuloma of the Mandible. *J Oral Maxillofac Surg* 1983; 11: 743-6.
11. Bonetti F, Pelosi G, Martignoni G, Mombello A, Zamboni G, Pea M, Scarpa A, Chilosi M. Peripheral Giant Cell Granuloma: Evidence for Osteoclastic Differentiation. *Oral Surg Oral Med Oral Pathol* 1990; 70: 471-5.
12. Flanagan AM, Nui B, Tinkler SM, Horton MA, Williams DM, Chambers TJ. The Multinucleate Cells in Giant Cell Granulomas of the Jaw Are Osteoclasts. *Cancer* 1988; 62: 1139-45.
13. Fanourakis G, Krithinakis S, Tosios KI, Sklavounou A, Tseleni-Balafouta S. Expression of Receptor Activator of NF-Kb Ligand and Osteoprotegerin in Peripheral Giant Cell Granulomas of the Jaws. *J Oral Pathol Med* 2010; 39: 687-9.
14. Eversole LR, Rovin S. Reactive Lesions of the Gingiva. *J Oral Pathol* 1972; 1: 30-8.
15. Buchner A, Shnaiderman A, Vared M. Pediatric Localized Reactive Gingival Lesions: A Retrospective Study From Israel. *Pediatr Dent* 2010; 32: 486-92.
16. Pandolfi PJ, Feleflı S, Flaitz CM, Johnson JV. An Aggressive Peripheral Giant Cell Granuloma in a Child. *J Clin Pediatr Dent* 1999; 23: 353-5.
17. Lima Gda S, Fontes ST, de Araújo LM, Etges A, Tarquinio SB, Gomes AP. A Survey of Oral And Maxillofacial Biopsies in Children: A Single-Center Retrospective Study of 20 Years in Pelotas-Brazil. *J Appl Oral Sci* 2008;16:397-402.

Yazışma Adresi

Dr. Ömür Dereci
Eskişehir Osmangazi University,
Faculty of Dentistry
Department of Oral and Maxillofacial Surgery
Meşelik Campus, 26480
Eskişehir, Turkey
E-mail: omurdereci@hotmail.com
Tel No: +902222391303
Fax No: +902222391273

